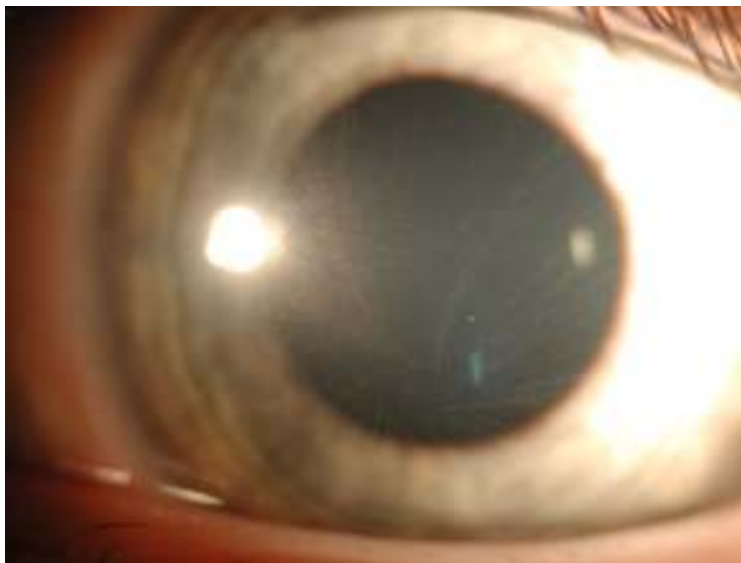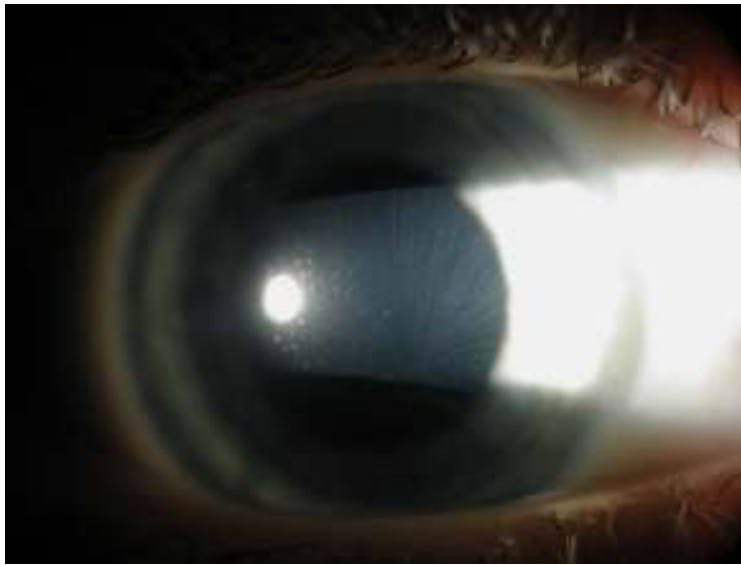


## Clinical Case Quiz: September 2008

Case History: An apparently healthy 13 y.o. white male presents for decreased distance vision OU (20/50 OD,OS) for ~6 months; near vision is 20/20 OU. He has never worn glasses. BCVA: -0.75 OU = 20/20 OD,OS. IOP was 15, 15 OD,OS and pupillary testing was normal w/o APD. Anterior segment shown below (same appearance OU), DFE was unremarkable OU. The patient is not on any medications and has no known allergies to medications.



1. What is the diagnosis?
2. What else may produce these corneal findings?
3. What causes this disease?
4. What systemic findings might be expected?
5. What are the other ocular manifestations of this disorder?

[Click here](#) to view the answers to these questions